CASE REPORT

Use of Dynamic Navigation Implant Surgery In Combination with An Immediate Loading Procedure

Dr. Jan D'haese
Dr. Johan Ackhurst
Prof. Dr. Hugo De Bruyn

Ghent University

INTRODUCTION

Although osseo-integration of dental implants is predictable[1] thorough pre-operative planning is a prerequisite for a successful treatment outcome[2]. Anatomic limitations as well as prosthetic considerations encourage the surgeon to obtain a very precise positioning of the implants. Historically, standard radiographic imaging techniques (intra-oral and panoramic) were available for investigation of potential implant sites.

Nowadays, it is well known that 3-dimensional CT scan based pictures allow a more reliable treatment planning than when only 2-dimensional data are available[3]. Transforming the CT scan images into a 3D virtual image can be achieved using computer software packages[3], allowing for a 3D viewing using Computer Aided Design (CAD) technology. For years, stereolithographic guided surgery seemed to be the golden standard in computer guided implant surgery. This technique has been well developed over last years and several scientific reports have been published regarding accuracy, complications, survival and success[4]. However, stereolithographic guided surgery has some major disadvantages compared to conventional implant surgery. The surgeon has to rely on a predesigned trajectory planned in the software, without being able to make intra-operative adjustments. Also the loss of tactile feeling during preparation and implant installation is a major drawback.

Real-time navigation seems to be a valuable alternative to stereolithographic (static) guided surgery as it offers the clinician some advantages compared to the former technique. Using real-time (dynamic) navigation one can avoid the fabrication of a stereolithographic template resulting in a less expensive treatment. As navigation is considered as a dynamic guided surgery system, changes to the treatment planning (location and size of the implants, number of the implants, flap or flapless...) can be easily made intra-operatively. Also the tactile feeling during the drilling procedure, as well as the manual control over the implant stability, is still present when using navigation surgery.

Since the last decade, there has been a shift in surgical and prosthetic protocols resulting in significant reduction of integration time of a dental implant. This is a logical consequence of the constant improvement of implant characteristics and components simplifying dental implant treatment. Guided surgery using implant simulation software can contribute to a better treatment planning as it provides a pre-operative view of the anatomical structures related to the future prosthodontics[5]. This fact could make immediate loading procedures easier and the clinician already knows in advance the potential location and dimension of the future restoration(s). Most of guided surgery procedures result in the

absence of a flap design. Minimizing the surgical flap can have advantages for soft tissue healing and patient comfort[6]. However, it has been shown that flapless freehanded surgery, regardless of surgical experience, leads to malpositioning of implants and consequently to bone perforations and dehisences[7]. This finding suggests that when using free-handed flapless surgery additional guiding during preparation of the implant bed as well as during implant installation is required. This is why navigation surgery can become an important tool in the future of dental implantology as it benefits from the advantages obtained using stereolithographic guided surgery and in the meanwhile solving some important drawbacks of stereolithographic involved procedures.

CASE PRESENTATION

The patient treated was a 21 year-old female consulting the dental office for replacement of both second premolars in the maxilla, at locus 15 and locus 25. Patient was in good general condition and she is a nonsmoker. She was treated before at the orthodontic department at Ghent University Hospital because of multiple agenesia. Intraoral examination revealed the absence of both lateral incisors and second premolars in the maxilla and both second premolars in the mandible. Periodontal screening showed no signs of pathology. The bone anchors used during the orthodontic treatment are still present in the second and fourth quadrant. Treatment involved placement of 2 dental implants in the edentulous regions of the maxilla. Both implants will be restored with 2 provisional crowns within 12 hours after implant installation (immediate loading).

Pre-operatively, an impression of the dental arch was taken using an irreversible hydrocolloid (Cavex CA37, fast set, Cavex Holland BV, Haarlem, The Netherlands) to fabricate a diagnostic cast. This cast was used as a model for the molding of the surgical stent; hereafter called NaviStent (Fig. 1). The NaviStent was fabricated in the dental clinic without the use of a dental laboratory or external production facility. The NaviStent served as a scanning template and is also worn by the patient during the surgery. Afterwards, the patient was sent to the CBCT and a scan was made with the NaviStent in place.

Figure 1: The NaviStent surgical stent

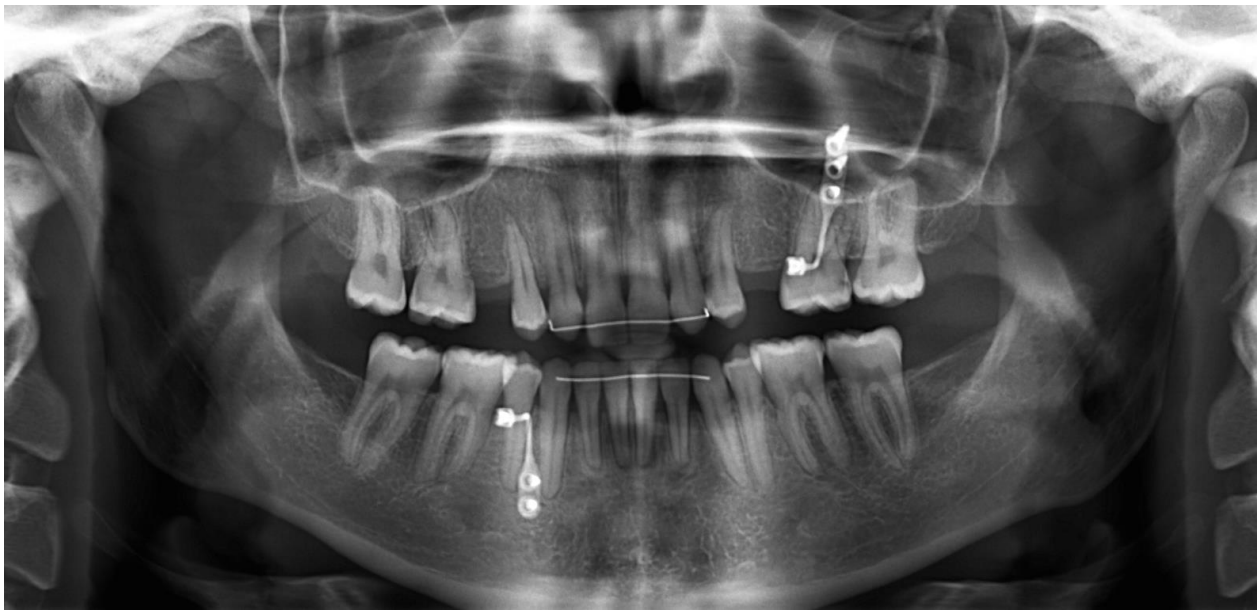

Figure 2: Pre-op panoramic image

Figure 3: Pre-op locus 15 and lateral image (above)

Figure 4: Pre-op locus 25 and lateral image (below)

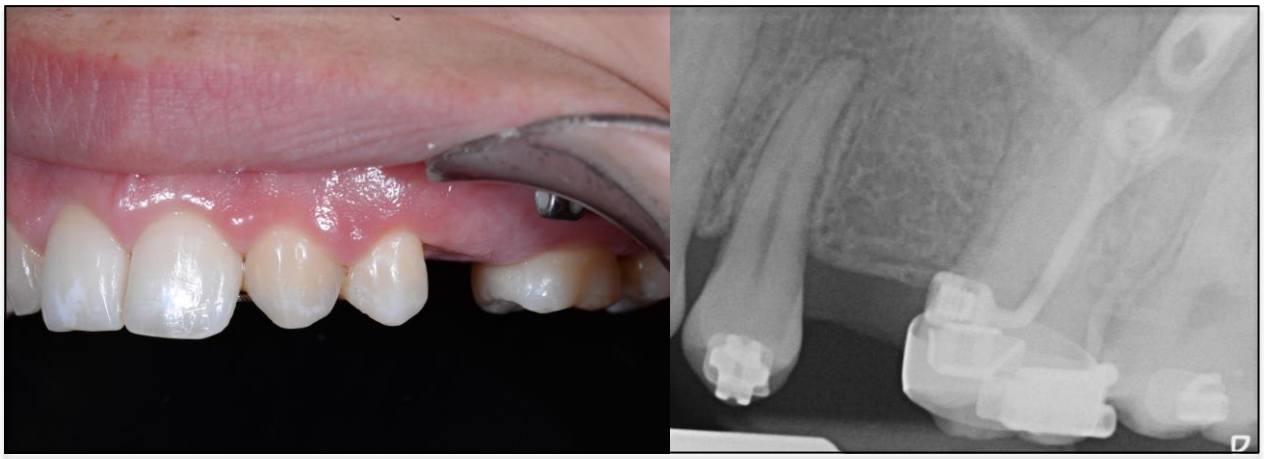

PLANNING PROCEDURE

A standard CBCT scan was performed according to the procedure outlined in the Navident scanning protocol from ClaroNav (ClaroNav Inc., Toronto, Canada). Cone-beam images were taken with a Planmeca Promax 3D Max with flat panel detector and isotropic voxels. The field of view used for this case was 50mm high and 100mm diameter and a voxel size of 200µm. Exposition parameters were 96kV and 10mA. Care was taken to align the field of view with the jaw and the Navident CT Marker, temporarily attached to the NaviStent for the duration of the scan.

All images were carefully reviewed and subsequently the CBCT images were converted into DICOM files (Digital Imaging and COmmunications in Medicine) and transformed into a 3-D virtual model using the Navident software system. The clinician who placed the virtual implants in the virtual 3-dimensional model also performed the actual surgeries. The potential locations for implant placement, and corresponding implant lengths and widths were planned in a prosthetic driven way. A distance of at least 3 mm from the neck of implant to the gingival zenith was applied, allowing the biological width to create a connective tissue contour around the abutments.

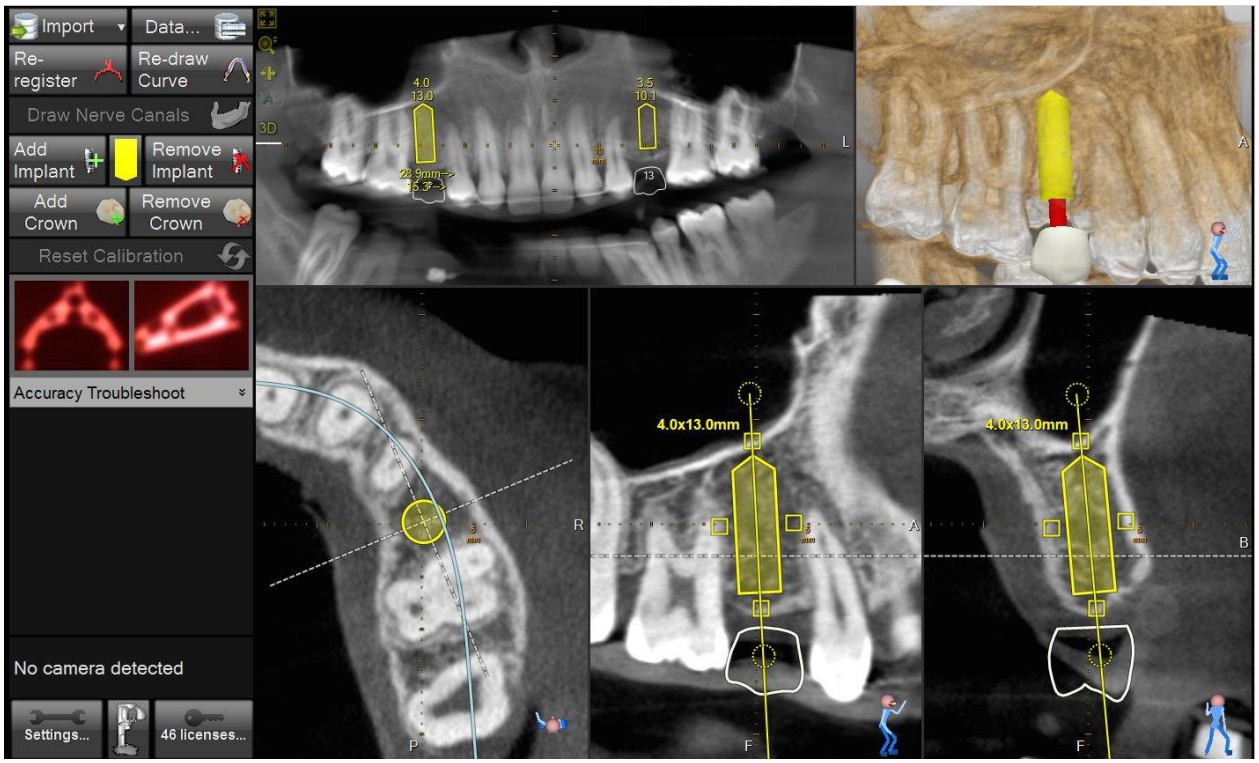

Figure 5: Planning in Navident

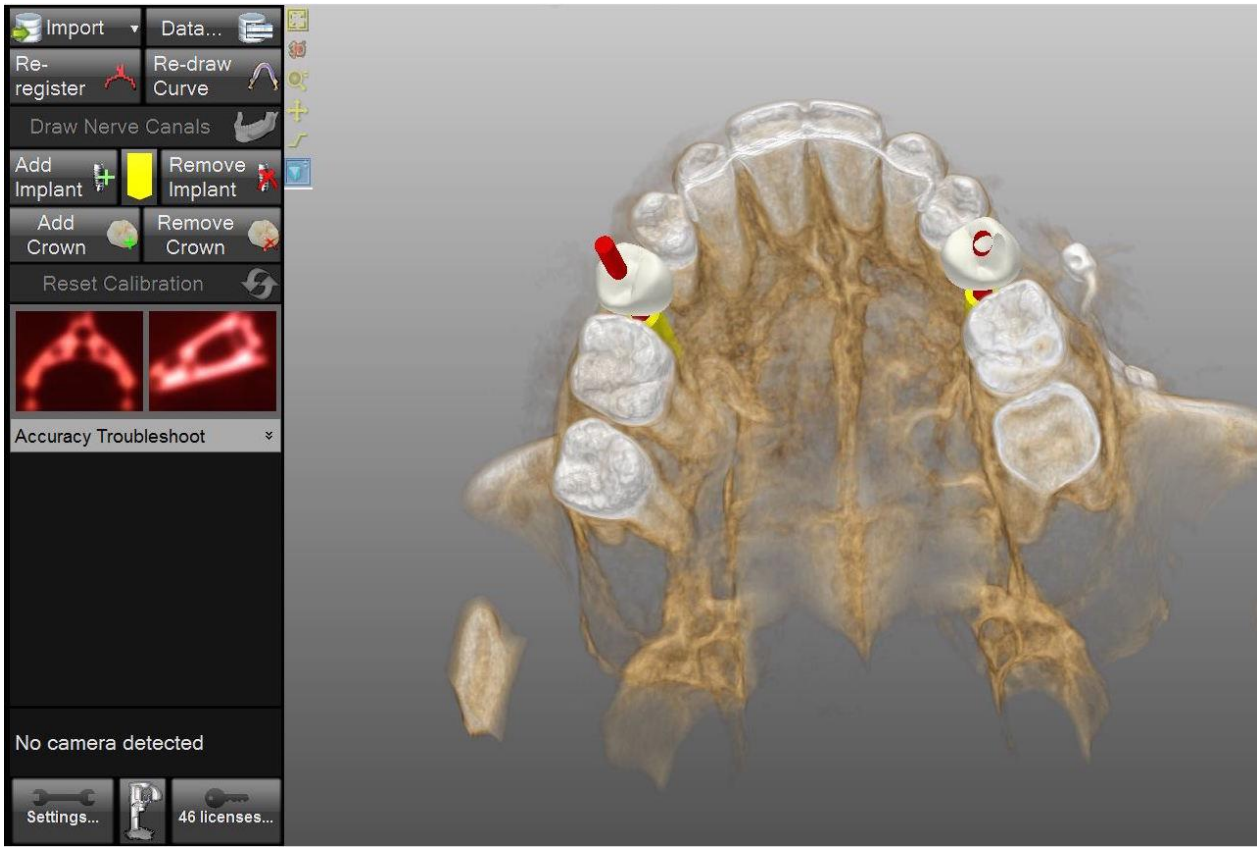

Figure 6: Planning in Navident

SURGICAL PROCEDURE

The surgery was performed under local-regional anesthesia. Appropriate aseptic and sterile conditions were implemented to prevent post-operative infections. Before the start of the intervention, the NaviStent was placed over the remaining teeth. The NaviStent was primarily fixated taking advantage of the undercuts of the remaining teeth and additionally by application of a denture adhesive (Corega®, GlaxoSmithKline Consumer Healthcare, Wavre , Belgium).

Before starting the osteotomies, the drilling axis of the handpiece used during the surgical procedure had to be calibrated. The osteotomies were prepared at maximum of 500 rpm using the Navident navigation system to guide the drilling procedure in real-time by indicating the desired drilling pathway on the computer screen. Prior to the use of each new drill, a calibration process was performed (Fig. 7, Fig. 8, Fig. 9) in order to determine the exact location of the drilling tip. No punching of the gingival tissues was performed prior to the preparation of the implant sites.

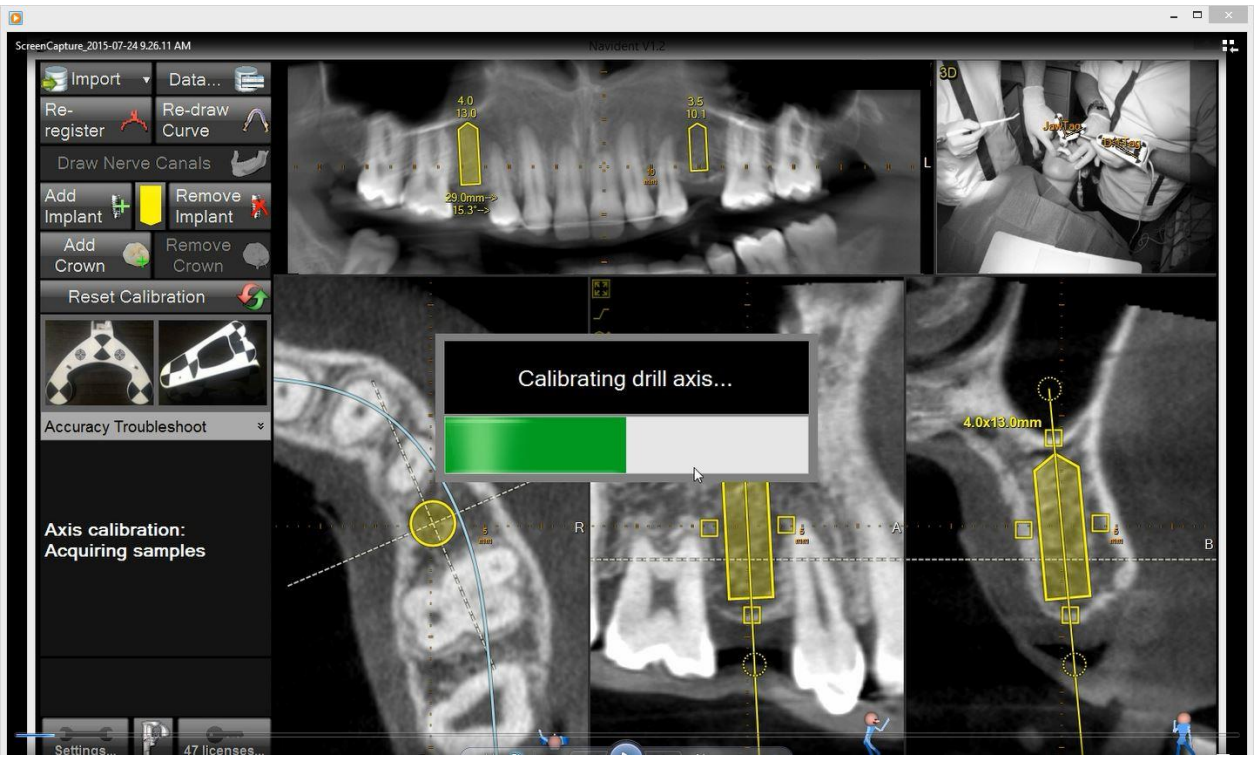

Figure 7: Calibration of the drill axis

Two Xpeed® Anyridge® implants (Megagen, Seoul, South-Korea) were installed. At locus 15; a 4 mm length and a 13 mm wide fixture was inserted whereas at locus 25 a 10 mm length and a 3,5 mm diameter wide implant was installed (Fig. 11, Fig. 12).

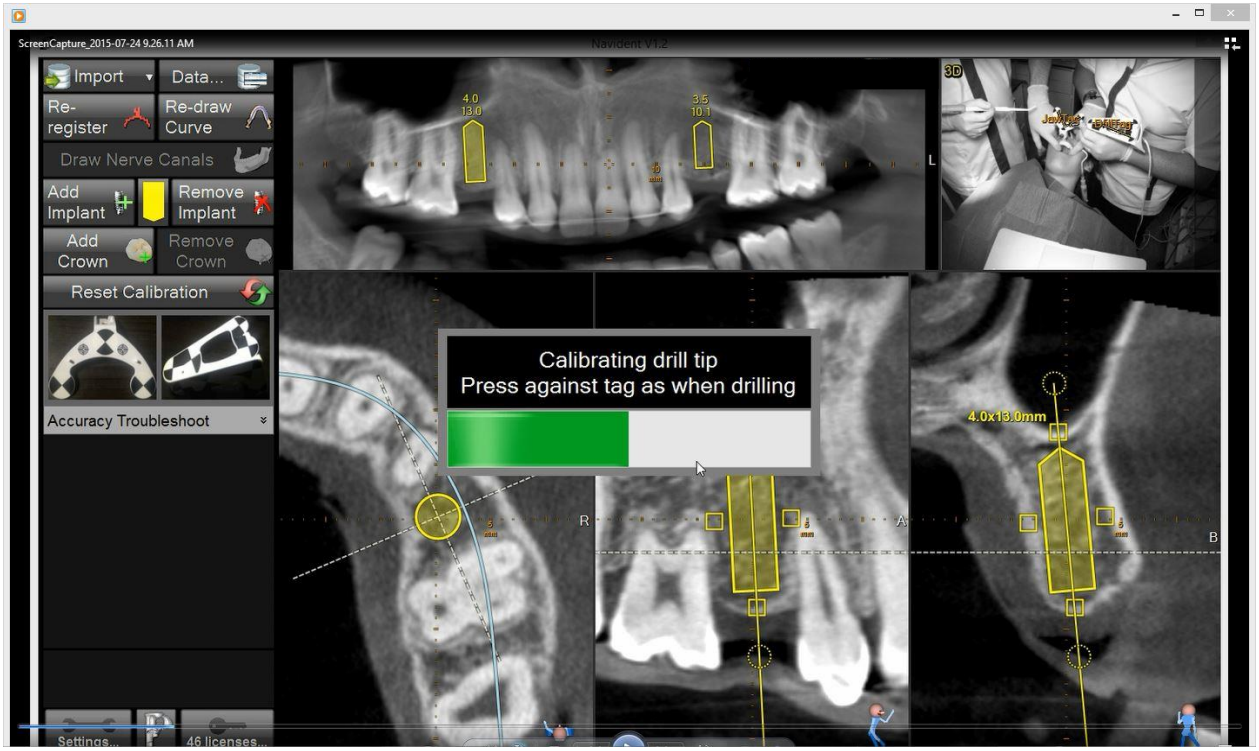

Figure 8: Calibration of the drill tip

Before installation of each implant, an extra calibration procedure was performed in order to be able to track the implant itself also in real-time during insertion. This means that both osteotomy preparation and the implant placement process are tracked in real time. The Navident tracking system uses an on screen visual representation of the surgical area and auditory cues to aid the clinician.

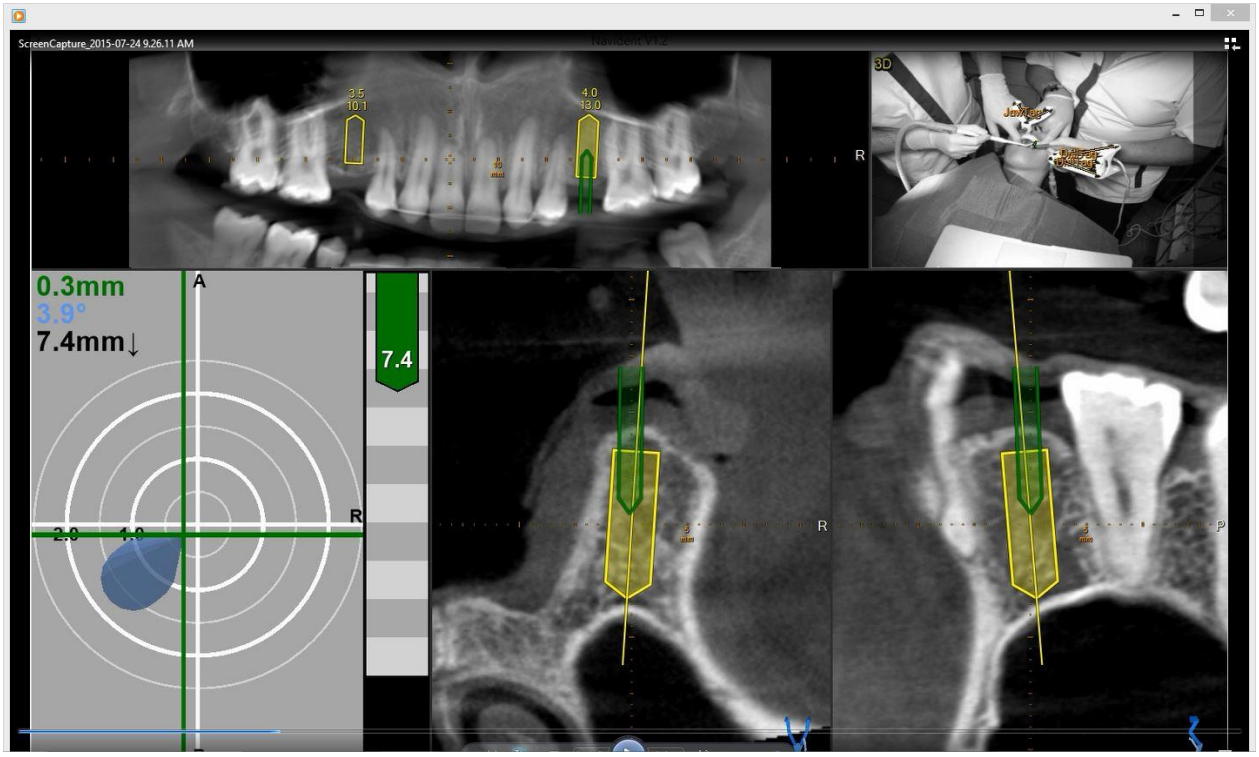

Figure 9: Surgical guidance by using Navident

After completion of the dental implant installation, a crown lengthening procedure was performed in the anterior maxillary region in order to ameliorate the esthetical outcome. It is beyond the purpose of this report to go more into detail regarding this procedure.

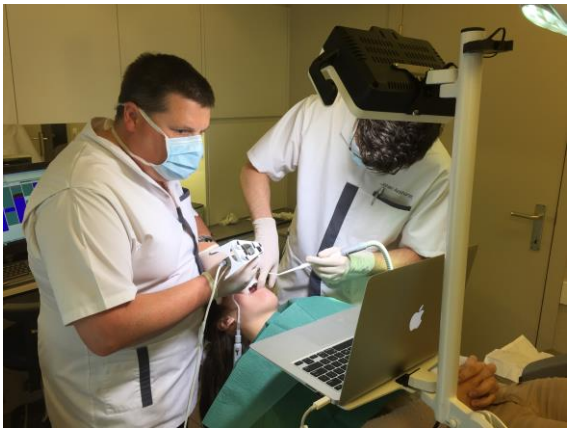

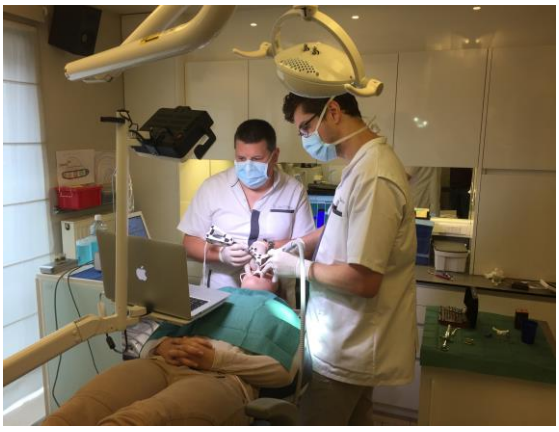

Figure 10: Surgical guidance by using Navident

Figure 12: Post-op locus 15 and 25

Figure 11: The Navident system from ClaroNav Inc.

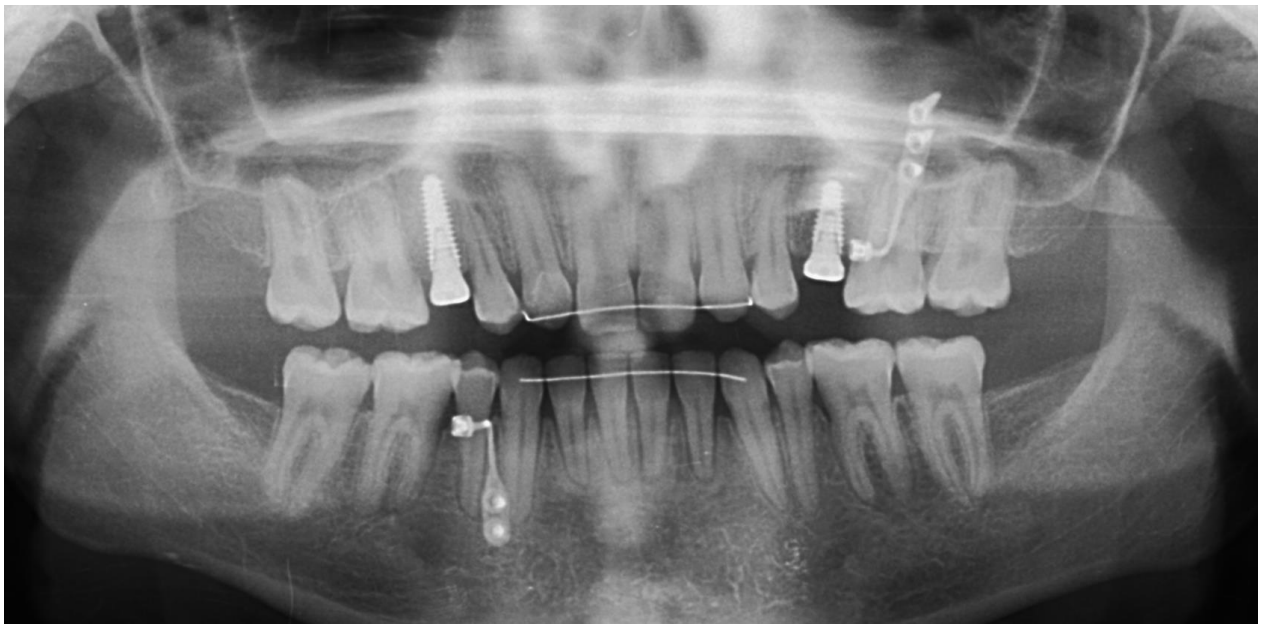

Figure 13: Post-op panoramic image

PROSTHETIC PROCEDURE

Immediately after implant installation, impression copings (Megagen, Seoul, South-Korea) for an open tray impression were screwed onto the implants and hand torqued (Fig. 14). An impression was made on implant level using a silicone material (Permadyne Penta H, ESPE Dental AG, Seefeld, Germany) within a plastic Position™Tray (ESPE Dental AG, Seefeld, Germany).

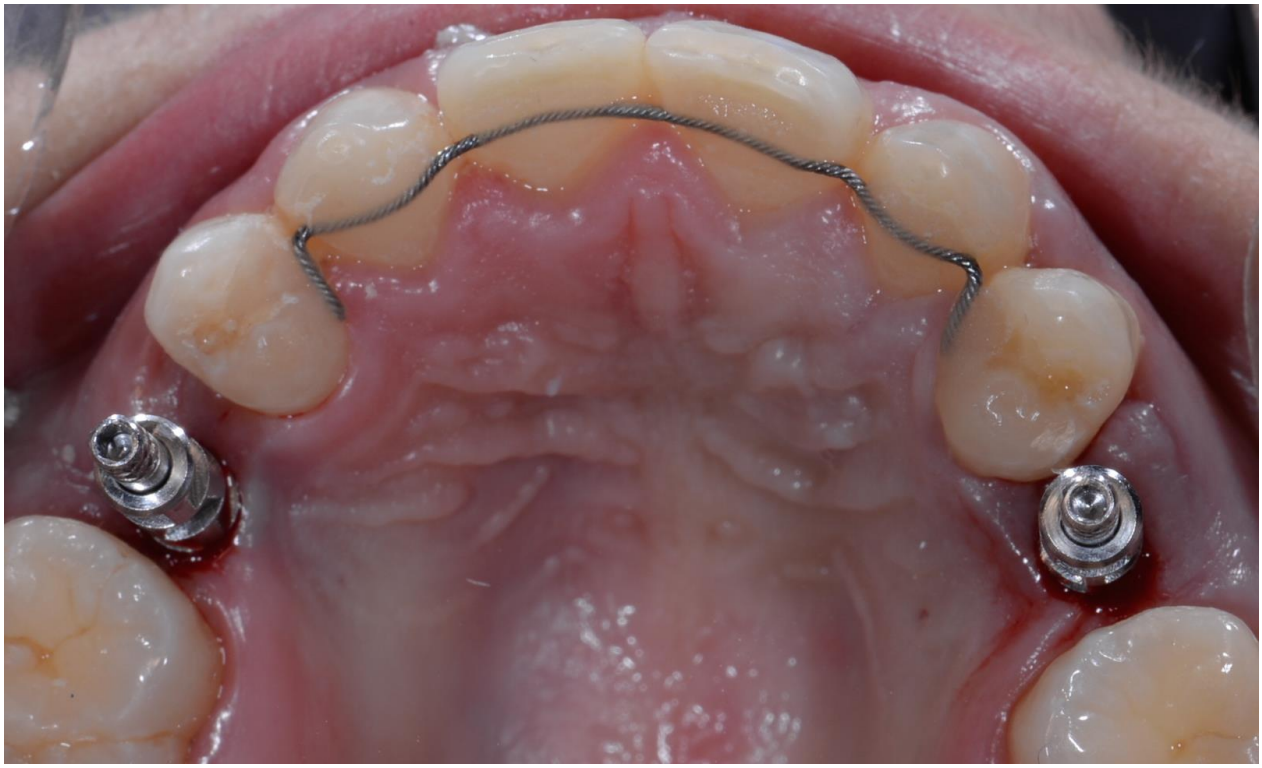

Figure 14: Post-op maxilla occusal

Within 8 hours, 2 temporary screw retained acrylic teeth were delivered to the patient and connected to each of the fixtures. The acrylic teeth were designed based on temporary titanium abutments. Occlusion and articulation were checked and corrected whenever necessary. All suprastructures were hand-torqued not exceeding a maximum of 15Ncm. No cantlevers were allowed on the provisional structures in order to avoid extensive non-axial forces. Postoperatively, the patient received a prescription for antibiotics (amoxicilline 1000 mg, 2x/d, 4 days), for non-steroidal anti-inflammatory drugs (ibuprofen 600mg, 3x/d) and for a mouthwash (chlorhexidine 0,12%, 2x/d). After 1 week, a post-operative visit was scheduled. No signs of infection or inflammation were present as the healing went on uneventfully.

Figure 15: Post-op frontal

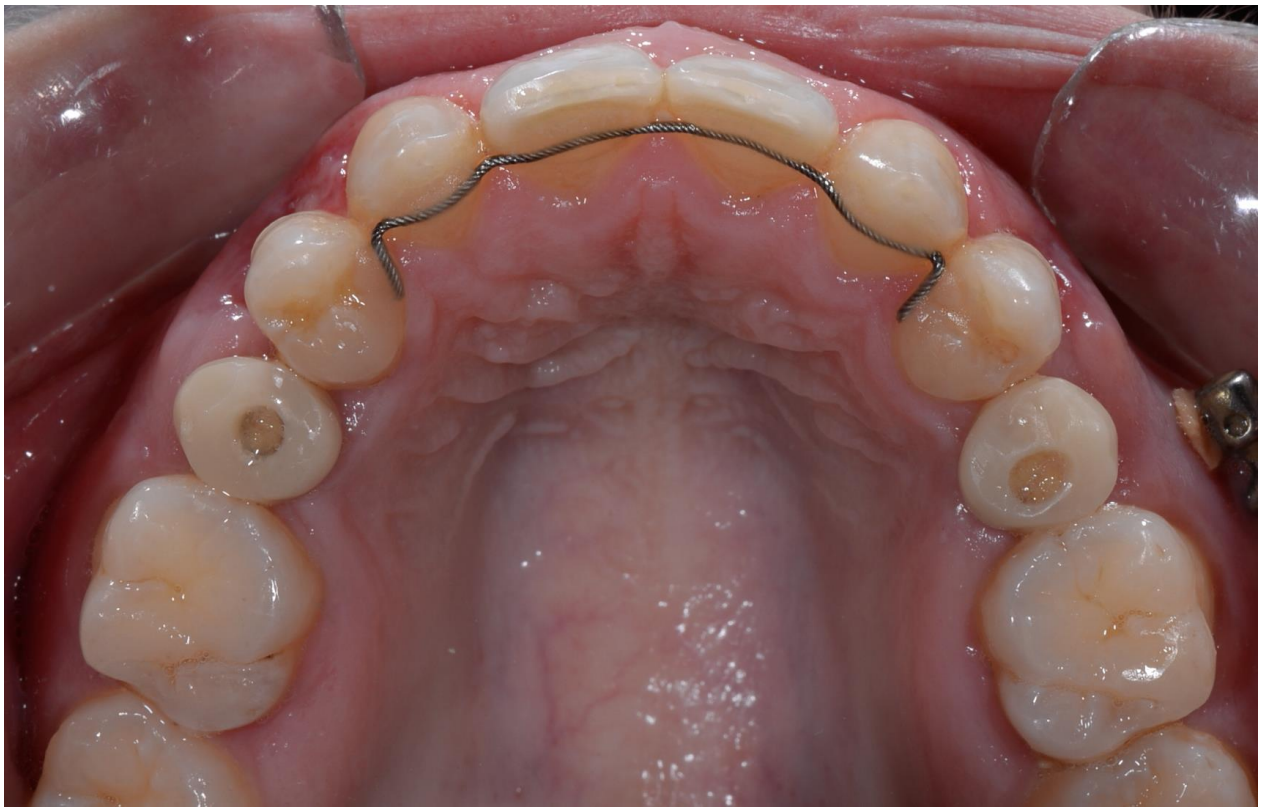

Figure 16: post-op maxilla occlusal (post loading)

CONCLUSIONS

This was the first immediate loading procedure based on the Navident navigation surgery system. There were no complications after a two-week postoperative follow-up. The patient reported no pain or swelling associated with the dental implant procedure. Further postoperative results are being tracked and reported as part of a pilot study being done at Ghent university.

Figure 17: Post-op lateral image position 15 and 25

REFERENCES

1. Albrektsson T, Dahl E, Enbom L, et al. Osseointegrated oral implants. A Swedish multicenter study of 8139 consecutively inserted Nobelpharma implants. J Periodontol 1988; 59:287–296.

2. Jacobs R, Adriansens A, Naert I, Quirynen M, Hermans R, van Steenberghe D. Predictability of reformatted computed tomography for preoperative planning of endosseous implants. Dentomaxillofacial Radiology 1999; 28,37–41.

3. Jacobs, R., Adriansens, A., Verstreken, K., Suetens, P. & van Steenberghe, D. Predictability of a three-dimensional planning system for oral implant surgery. Dentomaxillofacial Radiology 1999; 28:105–111.

4. D'haese J, Van De Velde T, Komiyama A, Hultin M, De Bruyn H. Accuracy and Complications Using Computer-Designed Stereolithographic Surgical Guides for Oral Rehabilitation by Means of Dental Implants: A Review of the Literature Clin Impl Dent Rel Res 2012; 14: 321–335.

5. D'haese J, Van De Velde T, Elaut L, De Bruyn H. A prospective study on the accuracy of mucosally supported stereolithographic surgical guides in fully edentulous maxillae.
Clin Implant Dent Relat Res. 2012; 14: 293-303.

6. Fortin T, Bosson JL, Isidori M, Blanchet E. Effect of flapless surgery on pain experienced in implant placement using an image-guided system. Int J Oral Maxillofac Implants. 2006 ; 21: 298-304.

7. Van de Velde T, Glor F, De Bruyn H. A model study on flapless implant placement by clinicians with a different experience level in implant surgery. Clin Oral Implants Res. 2008; 19: 66-72.