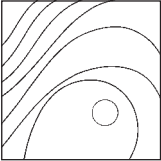


# Implant Placement Under Dynamic Navigation Using Trace Registration: Case Presentations



E. Todd Scheyer, DDS, MS<sup>1</sup>  
 George A. Mandelaris, DDS, MS<sup>2</sup>  
 Michael K. McGuire, DDS<sup>3</sup>  
 Mohamad A. AlTakriti, DDS<sup>4</sup>  
 Luigi V. Stefanelli, DDS, PhD<sup>5</sup>

*Trace registration is a new, alternative registration method for dynamic navigation implant surgery that eliminates the need for an artificial fiducial marker and stent to be present in the CBCT scan, substituting it with other high-contrast landmarks such as teeth, implants, or abutments. Clinical advantages include a streamlined, simplified workflow with fewer opportunities for error; elimination of presurgical steps associated with stent fabrication and imaging; and reduction in radiation risk. Sufficient high-contrast intraoral structures are a prerequisite for using this technique. This case series presents the trace registration protocol and workflow and reports on cases that demonstrate the application of this technology, including postoperative placement accuracy evaluation. Int J Periodontics Restorative Dent 2020;40:e241–e248. doi: 10.11607/prd.4479*

Dental surgical navigation systems track the jaw and drill tip in real time during osteotomy site preparation, with the actual drill tip location superimposed on the patient's computed tomography (CT) or CBCT image. Dynamic navigation allows the surgeon to continuously track the drill's position and, in real-time, visualize (and subsequently change) discrepancies in entry-point position and angle deviations compared to the optimal, prosthetically directed implant position in the software plan.<sup>1–7</sup> These systems require correlation of the CBCT scan used for virtual planning with the patient's physical jaw, which occurs through a process known as registration.

Traditionally, registration for dynamic navigation surgery requires a presurgical CBCT scan incorporating a metallic fiducial marker affixed to the patient's jaw via a thermoplastic stent, which subsequently becomes incorporated into the DICOM (Digital Imaging Communication in Medicine) dataset from CBCT imaging.<sup>2,3,5,7</sup> The CBCT scan is imported into the navigation system's computer, and the fiducial's image is detected by the software. During surgery, the CBCT scan is registered and correlated to the patient's arch using an optical tracking tag coupled to the stent and fixed to the operated arch. This allows for continuous tracking of the arch

<sup>1</sup>Private practice, Houston, Texas, USA; Department of Graduate Periodontics, University of Texas Health Science Center at San Antonio and Houston, Texas, USA.

<sup>2</sup>Private practice, Park Ridge, Oakbrook Terrace, and Chicago, Illinois, USA; Department of Graduate Periodontics, University of Illinois, College of Dentistry, Chicago, Illinois, USA; Department of Graduate Periodontics, University of Michigan, School of Dentistry, Ann Arbor, Michigan, USA.

<sup>3</sup>Private practice, Houston, Texas, USA; Department of Graduate Periodontics, University of Texas Health Science Center at San Antonio and Houston, Texas, USA; Department of Graduate Periodontics, University of Michigan School of Dentistry, Ann Arbor, Michigan, USA.

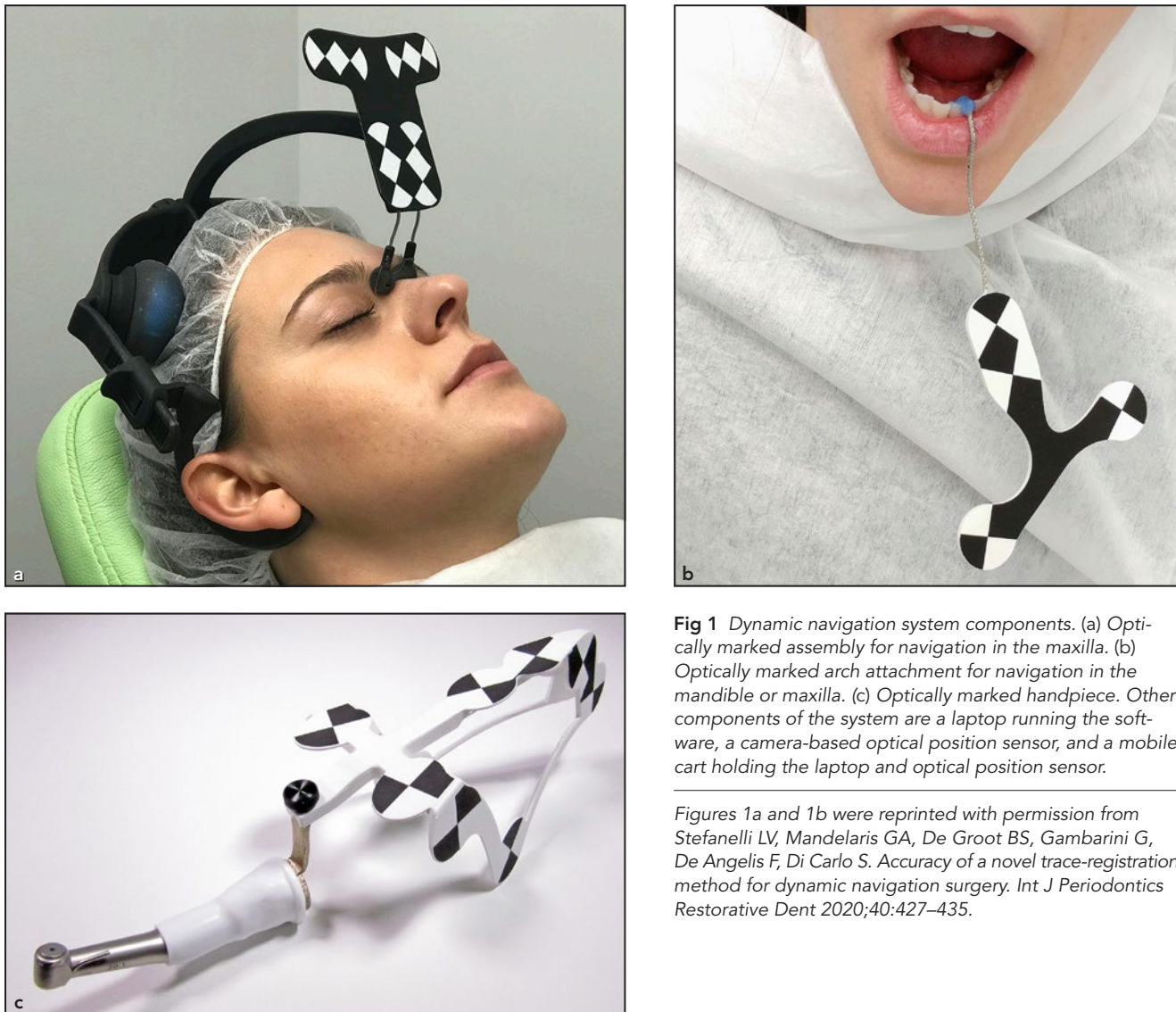
<sup>4</sup>Private practice, Houston, Texas, USA.

<sup>5</sup>Private practice, Rome, Italy.

Correspondence to: Dr E. Todd Scheyer, 3400 S Gessner Road, Suite 102, Houston, TX 77063, USA. Fax: 713-952-0614. Email: etsperio@periohealth.com

Submitted May 24, 2019; accepted October 6, 2019.

©2020 by Quintessence Publishing Co Inc.



**Fig 1** Dynamic navigation system components. (a) Optically marked assembly for navigation in the maxilla. (b) Optically marked arch attachment for navigation in the mandible or maxilla. (c) Optically marked handpiece. Other components of the system are a laptop running the software, a camera-based optical position sensor, and a mobile cart holding the laptop and optical position sensor.

Figures 1a and 1b were reprinted with permission from Stefanelli LV, Mandelaris GA, De Groot BS, Gambarini G, De Angelis F, Di Carlo S. Accuracy of a novel trace-registration method for dynamic navigation surgery. *Int J Periodontics Restorative Dent* 2020;40:427–435.

while maintaining its on-screen representation, regardless of the patient's motion during the operation. Using this method requires the stent to be seated on the patient's arch in the same position during the CBCT scan acquisition and during surgery.

Trace registration (TR; Navident 2.0 Trace and Place [TaP], ClaroNav) is an alternative registration method that eliminates the need for an artificial fiducial marker and stent to be present in the CBCT scan by sub-

stituting it with other high-contrast landmarks already present in the image, such as natural teeth, crowns, implants, or abutments.<sup>7</sup>

After using the system's software to virtually plan the prostheses and subsequent implants, the optical tracking tag is installed on the patient's arch. Registration of the CBCT scan to the patient's arch is then carried out by tracing the selected high-contrast landmarks in the patient's arch with an optically

marked tracing tool (Navident Tracer Tool and Tracer Tag, ClaroNav; Fig 1), which is similar to a stylus pen. A minimum of three (and up to six) teeth are traced, whereby a triangulated plane is created. A 3D volumetric mesh is generated from a software algorithm, which identifies the dental surfaces and registers them to the CBCT 3D rendering of patient anatomy.

This study presents the protocol for dynamic navigation using TR

and reports on cases treated in the authors' private practices, including accuracy outcomes.

## Materials and Methods

Patients requiring at least one implant for the treatment of partial or total edentulism or for the immediate placement into a postextraction site were selected from among the authors' (T.S., G.M., and L.S.) practices. All patients were treated in the authors' private practice settings. This retrospective analysis was submitted for approval to the Quorum Review IRB (Seattle, Washington). TR was performed for all patients using natural teeth as the high-contrast landmarks (ie, natural fiducials) according to the Navident 2.0 TaP protocol described below. Patients were informed of the nature and potential risks of the proposed treatment using TR for real-time verification and validation of positional accuracy, and an informed consent was reviewed and signed by each patient.

### *Stentless Workflow Using TR*

The TR-based system consists of the following components: (1) a laptop computer running the planning and guidance software; (2) an optically marked handpiece (Drill Tag); (3) an optically marked attachment for the patient arch (Head Tracker [ClaroNav] for maxillary cases; Jaw Tag [ClaroNav] for maxillary or mandibular cases); (4) a camera-based optical position sensor (Micron Tracker,

ClaroNav); (5) the Tracer Tool and Tracer Tag (ClaroNav); and (6) a mobile cart positioned over the patient to hold the laptop and optical position sensor.

### *Trace and Place*

Prior to osteotomy preparation, the laptop computer displaying the previously created virtual plan is positioned over the patient. An optical tracking tag is placed securely on the patient, and a second optical tracking tag is attached to the handpiece. Three or more teeth, preferably in a triangulated plane, are selected on the CBCT image and traced intraorally with the tracer tool, allowing the optical position sensor to collect data points on each tooth. The CBCT image locations to which each traced location should be matched are detected automatically by the software, based on the surface shape. Using these points, the software then registers the optical jaw attachment with the patient's CBCT image.<sup>7</sup> The accuracy of the TR can then be checked to ensure congruency between the actual anatomy and its software registration. This is performed using the tracer tool, which is placed on landmarks and compared to what is shown on the computer screen. If the computer's registration matches the patient, the registration is deemed correct.

Following registration, calibration of the drill axis to the micron tracker is performed using a calibration tool. Next, a drill is inserted into the implant handpiece and the

tip is calibrated to the software using the calibrator tool. Registration and calibration to the software occur through the micron tracker via visible light that is emitted to optical tracking tags (a jaw tag that represents the position of the patient and a drill tag that represents the position of the operator's handpiece). When the line of sight is unimpeded, the micron tracker continuously tracks the position and direction of the drill and the jaw, mapping their positions relative to the CBCT image and virtual plan. With this technology, real-time feedback and guidance are provided to the surgeon on the computer's screen (a virtual drill image, superimposed on the CBCT scan, is presented from three different directions). In addition, the position and direction of the drill, in relation to the virtually planned osteotomy, are integrated into a single crosshair (ie, target-view) display. This allows the surgeon to follow the planned osteotomy with the drill and immediately correct potential deviations from the plan.<sup>1</sup> It is important to remember that the micron tracker can only track what it sees. Therefore, the line of sight between the micron tracker and the jaw tag and drill tag must not be blocked. In addition, accuracy checks are critical to minimize errors in executing the plan; these checks are completed prior to each step to assure drill position congruency between the patient and what is shown on the computer screen. After osteotomy preparation, implants are inserted either under dynamic navigation or in a conventional freehand manner.

**Table 1 Summary of Accuracy Outcomes for Trace Registration Guided Navigation Surgery**

Surgeon	Site	Deviation/discrepancy			
		Entry, mm	Apex, mm	Apex depth, mm	Angulation, degrees
T.S.	Maxillary central incisor	0.50	0.55	0.08	1.45
G.M.	Maxillary central incisor	0.28	0.82	0.30	2.39
	Maxillary canine	0.49	1.36	1.27	0.98
	Maxillary lateral incisor	0.61	1.71	0.03	5.01
L.S.	Maxillary lateral incisor (immediate implant)	0.31	0.72	0.64	0.19
	Maxillary first premolar	0.58	1.12	0.17	2.64
	Pterygoid implant	0.78	0.43	0.28	1.65

Deviation values were assessed by comparing the final with the planned placements.

### Accuracy Evaluation

A postoperative CBCT scan was taken on each patient to evaluate accuracy of the preoperative plan compared to actual outcome position. A proprietary software (Navident EvalNav, ClaroNav) evaluates placement accuracy by matching the preoperative CBCT image and virtual plan with the postoperative scan on the basis of common anatomical landmarks. Superimposition of the two scans was performed by persons not involved in the treatment protocol. Deviations in entry-point position, apex position, and angular discrepancies are presented visually and numerically.<sup>3</sup> Table 1 summarizes the accuracy and precision outcomes for all five cases treated with this new methodology. All patients were followed up postoperatively to assess tissue health and implant integration.

### Select Cases

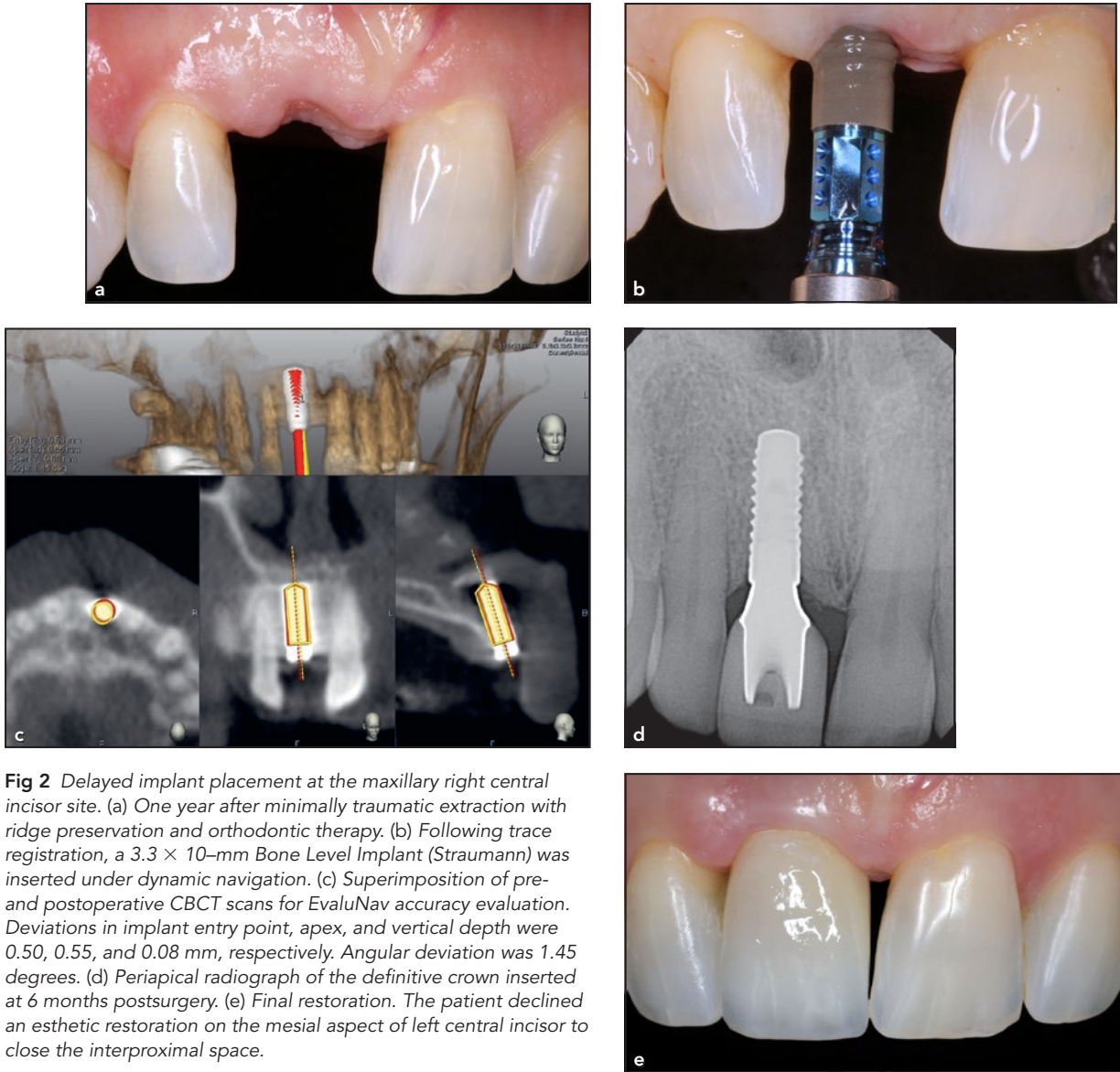
#### Case 1

Treatment of a case in the esthetic zone is shown in Fig 2. A 63-year-old woman presented to the author's (T.S.) practice with a history of trauma to her maxillary right central incisor and a diagnosis of internal root resorption. The right central incisor was extracted with a minimally traumatic technique, and the socket was grafted with mineralized freeze-dried cortical bone (AlloGraft GC, Straumann). After 1 month of healing, orthodontic treatment was initiated using clear aligners (Invisalign, Align Technology). At 1 year postextraction, it was determined that bone and soft tissue dimensions and the mesiodistal space were adequate for implant insertion (Fig 2a). A preoperative CBCT scan was taken and imported into the dy-

namic navigation software for prosthetically guided crown and implant planning.

After minimal flap elevation, the osteotomy was prepared under dynamic navigation to enhance the accuracy of site location, and a  $3.3 \times 10$ -mm Bone Level Implant (Straumann) was inserted (Fig 2b). A titanium  $4.8 \times 2$ -mm Narrow CrossFit Healing Abutment (Straumann) was placed for a semisubmerged healing protocol. A postoperative CBCT scan was taken for accuracy evaluation (Fig 2c).

At 3 months postinsertion, the implant was uncovered. A TRIOS (3Shape) digital impression was taken both with and without a scan body for the fabrication of a screw-retained provisional restoration. The definitive crown was inserted at 6 months (Figs 2d and 2e).



**Fig 2** Delayed implant placement at the maxillary right central incisor site. (a) One year after minimally traumatic extraction with ridge preservation and orthodontic therapy. (b) Following trace registration, a 3.3 × 10-mm Bone Level Implant (Straumann) was inserted under dynamic navigation. (c) Superimposition of pre- and postoperative CBCT scans for EvaluNav accuracy evaluation. Deviations in implant entry point, apex, and vertical depth were 0.50, 0.55, and 0.08 mm, respectively. Angular deviation was 1.45 degrees. (d) Periapical radiograph of the definitive crown inserted at 6 months postsurgery. (e) Final restoration. The patient declined an esthetic restoration on the mesial aspect of left central incisor to close the interproximal space.

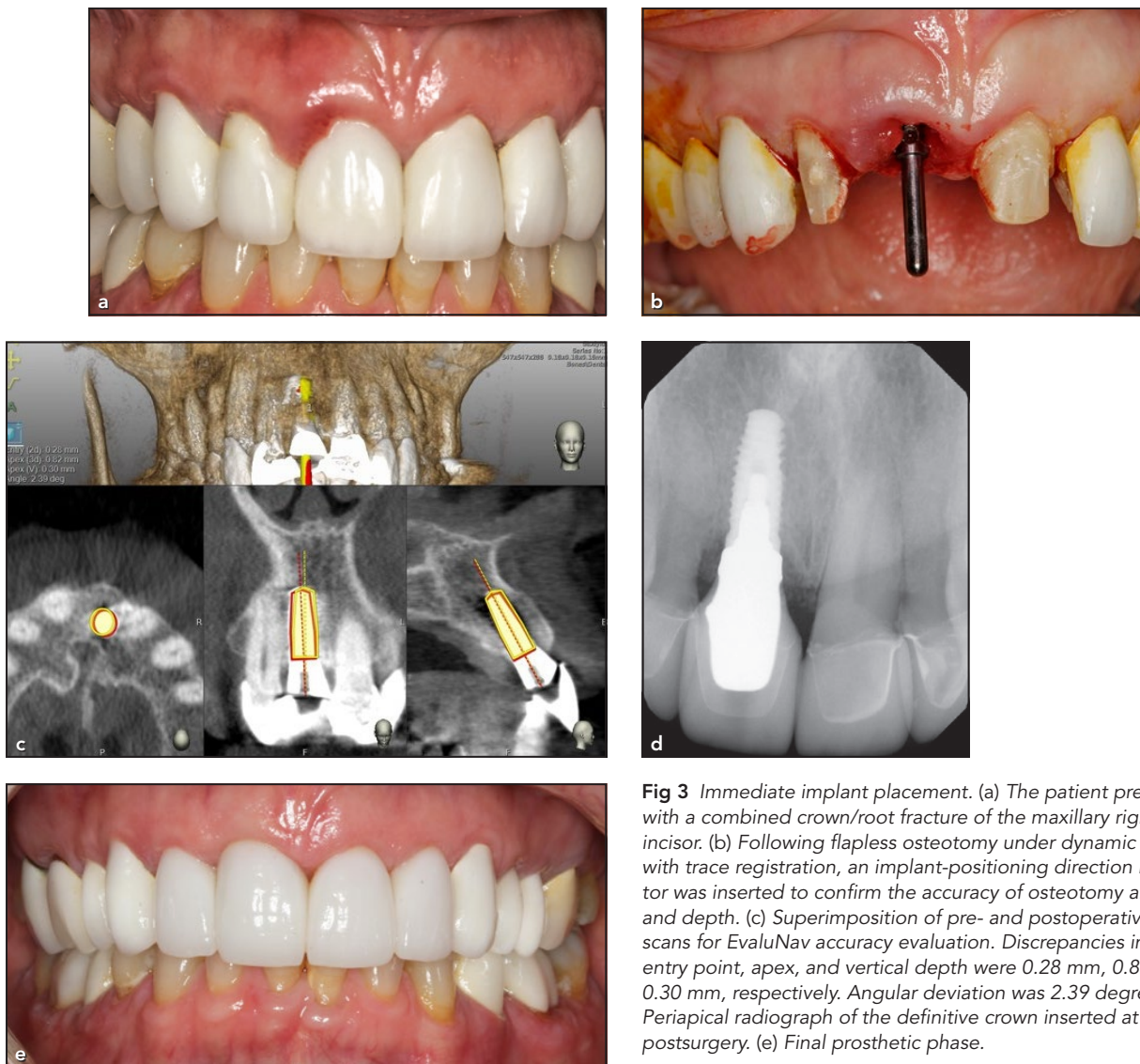
## Case 2

Figure 3 shows the treatment of a 72-year-old woman who presented to the author's (G.M.) practice with a combined crown/root fracture of the maxillary right central incisor (Fig 3a). She was presented with treatment options of forced orthodontic eruption or extraction and immediate implant placement un-

der dynamic navigation, which the patient selected in part because of the shorter treatment time and possibility of a flapless surgical protocol. A preoperative CBCT scan was used to create the virtual surgical and prosthodontic implant plan.

After minimally traumatic extraction, the presence of an intact buccal bone wall was confirmed. The maxilla was registered to the

virtual plan by tracing natural teeth. Flapless osteotomy and immediate placement of a non-platform-switched NanoTite Certain 4 × 11.5-mm implant (Zimmer Biomet) were performed using dynamic navigation to enhance accuracy (Fig 3b). A matrix of xenograft and collagen was enhanced with platelet-rich fibrin and applied to the gap between the implant and socket walls,



**Fig 3** Immediate implant placement. (a) The patient presented with a combined crown/root fracture of the maxillary right central incisor. (b) Following flapless osteotomy under dynamic navigation with trace registration, an implant-positioning direction indicator was inserted to confirm the accuracy of osteotomy angulation and depth. (c) Superimposition of pre- and postoperative CBCT scans for EvalNav accuracy evaluation. Discrepancies in implant entry point, apex, and vertical depth were 0.28 mm, 0.82 mm, and 0.30 mm, respectively. Angular deviation was 2.39 degrees. (d) Periapical radiograph of the definitive crown inserted at 4 months postsurgery. (e) Final prosthetic phase.

and a customized healing abutment was placed for nonsubmerged healing and to optimize the soft tissue form.

Following placement of the healing abutment (BellaTek Encode, Zimmer Biomet), a digital impression (TRIOS) and postoperative CBCT scan (Fig 3c) were taken. A customized healing abutment was then seated to allow for preservation of the emergence form and soft tissue contours. The definitive

custom abutment and crown were delivered at 4 months postsurgery (Figs 3d and 3e).

### Discussion

TR has distinct advantages for both patient and surgeon, with a simpler workflow than fiducial-dependent options.<sup>2,3,7</sup> While all surgical navigation systems require registration of the patient's CBCT to the actual

patient, with TR, the same diagnostic CBCT can be used for both planning and navigation surgery, reducing the risk of inaccuracies in the planning-to-placement process and also reducing radiation risk to the patient by eliminating additional imaging.<sup>7</sup> Moreover, depending on the clinical case, it is possible to use a CBCT scan with a small field of view so long as a triangulated plane can be produced. Because an existing recent CBCT scan can be used,

lack of on-site CBCT equipment is not an impediment to navigated implant placement. Scanning can be done in full occlusion, allowing for more precise prosthetic planning. TR also enables tracking of the arch with unimpeded, stent-free access to the surgical field.<sup>7</sup>

TR does not significantly affect the planning and guidance functions of the dynamic navigation system. The same accuracy checks should be performed to assess the safety and efficacy of navigated drilling and implant placement at each step in the operation. This further ensures safety and accuracy when carrying out the surgical plan. However, if the accuracy check fails, the cause can more easily and immediately be addressed and corrected, as TR eliminates the irreversible errors associated with fiducial-based presurgical preparations such as stent molding, trimming, and positioning on the arch.

Studies have reported on the accuracy of implants placed using dynamic navigation with fiducial-based registration in partially<sup>2,3,8</sup> and totally edentulous patients.<sup>8</sup> In the present case series, TR led to accurate placement compared to planned positions when used by three different surgeons in differing case types, including the esthetic zone as well as immediate and pterygoid implant protocols (Table 1). Placement accuracy was similar to that of fiducial-based navigation,<sup>3,7-9</sup> which itself has been shown to have similar accuracy to guided surgery using a static surgical template,<sup>3</sup> and greater accuracy than freehand placement.<sup>2,3</sup> TR allowed

flapless placement of a pterygoid implant<sup>10,11</sup> with a high degree of accuracy (Table 1), allowing the surgeon (L.S.) to precisely engage the pterygoid plate while respecting anatomical landmarks and safety limits.

Dynamic navigation with TR is best utilized in the esthetic zone, where precision and accuracy are of utmost importance. When placement accuracy is lacking, esthetic and biologic outcomes can be negatively impacted. Long-term studies on the prevalence of peri-implantitis bone loss range from 3% to as high as 47%.<sup>12</sup> It has been proposed that peri-implantitis may (in some situations) be related to modifiable factors, among which surgical trauma and implant malpositioning can be triggered or prevented in the surgical setting.<sup>13</sup> Placement too far buccally may trigger crestal bone loss and was the primary local factor associated with development of peri-implantitis in a study by Monje et al.<sup>14</sup>

Limitations to the use of TR include the prerequisites of a current, accurate CBCT scan and sufficient high-contrast surfaces accessible for tracing. From tracing and throughout navigated drilling/placement, the tracking tag must remain in a fixed position relative to the arch. If moved, registration can be compromised and should be repeated. The present case series reports on experienced surgeons in private-practice settings. Because osteotomy preparation and implant placement are still subject to operator-dependent errors, it is unclear if similar results would be obtained by other sur-

geons with differing skill levels or in different settings.

TR is a recent advancement in the field of computer-aided implant therapy. Based on these preliminary results, randomized, controlled studies comparing the use of TR with static guidance are merited to confirm its accuracy, safety, efficacy, and efficiency. Future applications of TR include the development of protocols for its use in edentulous patients in whom high-contrast landmarks for tracing must first be established.

## Conclusions

TR represents a significant improvement over fiducial-dependent protocols used with dynamic navigation; by streamlining and simplifying the dynamic navigation workflow, it has the potential to facilitate and encourage the use of navigation technology by clinicians. With trace registration, dynamically navigated osteotomy preparation can be accomplished with less radiation and less presurgical preparation. TR can prove to be an alternative registration method if controlled studies with statistical significance can demonstrate that it is more accurate than the conventional fiducial-based registration. A randomized controlled trial is in the development stage to answer this question. Precise virtual treatment planning, accessible high-contrast intraoral structures for tracing, and intrasurgical verification to achieve placement accuracy are keys to successful application of this technology.

## Acknowledgments

The authors declare no financial conflicts of interest. Drs Scheyer, Mandelaris, and Stefanelli are key opinion leaders for Navident. Data collection, IRB submission, and manuscript preparation were supported by an educational grant from ClaroNav.

## References

- Block MS, Emery RW. Static or dynamic navigation for implant placement—Choosing the method of guidance. *J Oral Maxillofac Surg* 2016;74:269–277.
- Block MS, Emery RW, Cullum DR, Sheikh A. Implant placement is more accurate using dynamic navigation. *J Oral Maxillofac Surg* 2017;75:1377–1386.
- Block MS, Emery RW, Lank K, Ryan J. Implant placement accuracy using dynamic navigation. *Int J Oral Maxillofac Implants* 2017;32:92–99.
- Casap N, Wexler A, Persky N, Schneider A, Lustmann J. Navigation surgery for dental implants: Assessment of accuracy of the image guided implantology system. *J Oral Maxillofac Surg* 2004;62(suppl 2):116–119.
- D'haese J, Ackhurst J, Wismeijer D, De Bruyn H, Tahmaseb A. Current state of the art of computer-guided implant surgery. *Periodontol 2000* 2017;73:121–133.
- Emery RW, Merritt SA, Lank K, Gibbs JD. Accuracy of dynamic navigation for dental implant placement—Model-based evaluation. *J Oral Implantol* 2016;42:399–405.
- Mandelaris GA, Stefanelli LV, DeGroot BS. Dynamic navigation for surgical implant placement: Overview of technology, key concepts, and a case report. *Compend Contin Educ Dent* 2018;39:614–621.
- Stefanelli LV, DeGroot BS, Lipton DI, Mandelaris GA. Accuracy of a dynamic dental implant navigation system in a private practice. *Int J Oral Maxillofac Implants* 2019;34:205–213.
- Somogyi-Ganss E, Holmes HI, Jokstad A. Accuracy of a novel prototype dynamic computer-assisted surgery system. *Clin Oral Implants Res* 2015;26:882–890.
- Candel E, Peñarrocha D, Peñarrocha M. Rehabilitation of the atrophic posterior maxilla with pterygoid implants: A review. *J Oral Implantol* 2012;38(Spec Issue 1):461–466.
- Cucchi A, Vignudelli E, Franco S, Corinaldesi G. Minimally invasive approach based on pterygoid and short implants for rehabilitation of an extremely atrophic maxilla: Case report. *Implant Dent* 2017;26:639–644.
- Chan HL, Lin GH, Suarez F, MacEachern M, Wang HL. Surgical management of peri-implantitis: A systematic review and meta-analysis of treatment outcomes. *J Periodontol* 2014;85:1027–1041.
- Monje A, Galindo-Moreno P, Canullo L, Greenwell H, Wang H. Editorial: From early physiological marginal bone loss to peri-implant disease: On the unknown local contributing factors. *Int J Periodontics Restorative Dent* 2015;35:764–765.
- Monje A, Galindo-Moreno P, Tözüm TF, Suárez-López del Amo F, Wang H. Into the paradigm of local factors as contributors for peri-implant disease: Short communication. *Int J Oral Maxillofac Implants* 2016;31:288–292.